

Subcutaneous Hematoma Associated with Manual Cervical Massage during Carotid Artery Stenting

A Case Report

A. TSURUMI⁴, Y. TSURUMI², M. NEGORO³, K. YOKOYAMA⁴, M. OHEDA⁴, N. SUSAKI⁴, S. TSUGANE⁴, T. TAKAHASHI⁴, S. MIYACHI¹

¹ Nagoya University Graduate School of Medicine; Nagoya, Japan

² Department of Neurosurgery, Japanese Red Cross Nagoya Daiichi Hospital; Nagoya, Japan

³ Department of Neurosurgery, Fujita Health University; Toyoake, Japan

⁴ Department of Neurosurgery, National Hospital Organization Nagoya Medical Center; Nagoya, Japan

Key words: carotid artery stenting, cervical hemorrhage, manual compression

Summary

We describe a patient with subcutaneous hematoma associated with manual cervical massage during carotid artery stenting.

A 73-year-old man with left cervical carotid artery stenosis presented with left amaurosis fugax. We performed carotid artery stenting using distal embolic protection with balloon occlusion. Dual antiplatelet therapy was maintained in the periprocedural period and an anticoagulant agent was administered during the procedure. Because the aspiration catheter became entrapped by the stent, it did not reach the distal side of the stenotic lesion, and manual compression of the cervical region was therefore performed. Immediately afterwards, a subcutaneous hemorrhage occurred in the cervical region. There was no postoperative dyspnea due to enlargement of the hematoma, which was absorbed spontaneously.

Cervical subcutaneous hematoma can occur in the cervical region due to cervical massage in patients who are receiving adjuvant antiplatelet therapy and anticoagulation therapy.

Introduction

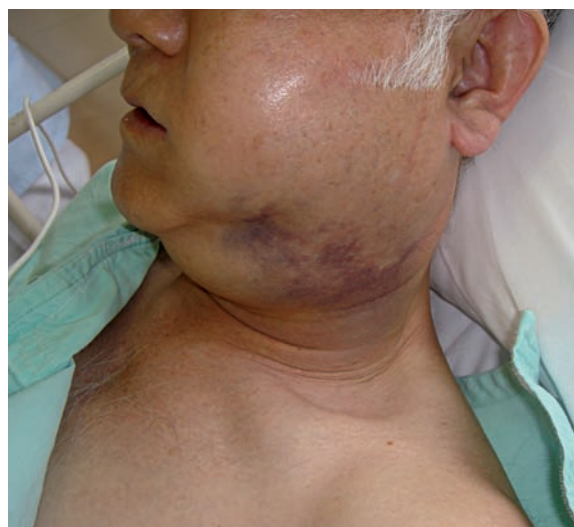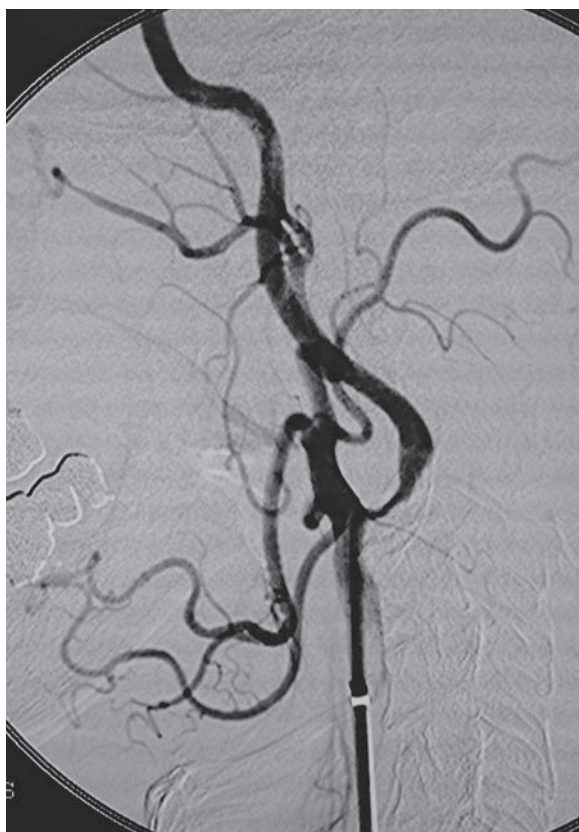
Cervical subcutaneous hematoma is a rare complication of carotid artery stenting (CAS)¹. Because dual antiplatelet and anticoagulant

therapy are administered during the periprocedural period of CAS, there is a tendency for hematomas to enlarge dramatically should hemorrhage occur. Reported causes of cervical hematoma include arterial perforation by the guide wire during the procedure and vessel rupture due to over-inflation of the percutaneous transluminal angioplasty (PTA) balloon^{2,3}. To the best of our knowledge, the literature contains no reports of manual compression of the cervical region⁴ causing the formation of a cervical subcutaneous hematoma, as the authors experienced. The authors report the present case because cervical hematoma is a complication that can have a detrimental effect on prognosis due to compression of the trachea, causing dyspnea.

Case Report

History

This 73-year-old man presented with left amaurosis fugax. He was examined in the Department of Neurology, where left cervical carotid artery stenosis was identified by magnetic resonance angiography (MRA) and carotid ultrasonography, and he was referred to the Department of Neurosurgery in May 2009. The patient was started on oral clopidogrel (75 mg once daily) and aspirin (100 mg once daily), which was



↑ *Figure 2* The left cervical area immediately after the procedure. Immediately after manual compression of the neck, the patient complained of pain in the left cervical area, and a hematoma was observed.

← *Figure 1* Left common carotid artery angiography (lateral view) before stenting showing a 70% stenosis at the origin of the left internal carotid artery.

maintained during the perioperative period. Residual platelet reactivity measured by the VerifyNow Assay (Accumetrics Inc., San Diego, CA, USA) was 481 Aspirin Reaction Units for aspirin and 109 P2Y12 Reaction Units for clopidogrel, respectively; these results indicated that both antiplatelet agents were at therapeutic levels.

Examination

On admission, the patient had no neurological deficit. Brain magnetic resonance imaging showed no cerebral infarction. Cervical MRA demonstrated severe stenosis of the left cervical carotid artery. Carotid ultrasonography also revealed severe stenosis of the left cervical carotid artery, with hypochoic plaque and calcification. Left common carotid angiography indicated 70% stenosis of the left cervical carotid artery according to North American Symptomatic Carotid Endarterectomy Trial⁵ (NASCET) Criteria (Figure 1). Right common carotid angiography demonstrated a 70% stenosis of the petrous portion of the right internal carotid artery. Aortography indicated that the left common carotid artery originated from the brachiocephalic artery.

Carotid Artery Stenting Procedure and Post Treatment Course

Local anesthesia was administered to the patient. We then intravenously administered 4000 units of heparin to achieve an activated coagulation time of 258 s. A 90-cm 6-French guide sheath (Shuttle-SL; Cook Medical, Bloomington, IN, USA) was inserted into the right radial artery and advanced until its tip reached the left common carotid artery by means of a coaxial system. A 125-cm 4-French catheter (Cerulean G; Medikit, Tokyo, Japan) and an angled 0.035-inch hydrophilic guidewire (Radifocus Guide wire M; Terumo, Tokyo, Japan) were inserted into the 6-French guide sheath by means of the coaxial system, enabling easy insertion of the tip of the sheath as far as the left common carotid artery. There was no arterial penetration by the wire or catheter. Using a roadmap, a PercuSurge GuardWire (Medtronic, Minneapolis, MN, USA) was advanced into the distal cervical internal carotid artery. After distal embolic protection with balloon occlusion, balloon angioplasty with a 4×40-mm Sterling balloon (Boston Scientific, Natick, MA, USA) (inflated to 6 atm/30 s) resulted in suboptimal recanalization,

therefore a 10×40-mm Precise carotid stent (Cordis, Miami Lakes, FL, USA) was advanced over the wire and deployed across the stenotic lesion in the internal and common carotid arteries. The residual stenosis was treated by temporary inflation of a 5×20-mm Sterling balloon (inflated to 6 atm/15 s) in the waist (residual stenosis) of the stented lesion. When an aspiration catheter (Eliminate; Terumo) was then advanced to the vicinity of the PercuSurge GuardWire balloon, its tip caught on the strut of the Precise stent and could not be advanced further. Measures such as swallowing saliva, turning the head to the right and left, and inserting the 0.035-in guide wire into the aspiration lumen of the Eliminate catheter were ineffective, and the Eliminate catheter could only be advanced to the vicinity of the PercuSurge GuardWire balloon after manual compression of the left cervical region to change the direction of the internal carotid artery.

Dispersed plaque and blood were aspirated from the eliminate catheter, but immediately after manual compression of the neck the patient complained of pain, and a left cervical hematoma was observed (Figure 2). The patient did not experience dyspnea. Angiography of the left common carotid artery was immediately performed, but this showed no extravasation of contrast medium. The stenosis was adequately dilated (Figure 3). The sheath was removed immediately at completion of the procedure, and hemostasis was obtained using a radial artery compression device. Activated coagulation time after completion was 230 s. Cervical computed tomography was performed immediately, and showed displacement of the trachea to the right by a large left cervical subcutaneous hematoma (Figure 4). The patient was transferred to the Neurological Care Unit and remained neurologically intact. No new anticoagulation therapy was added after surgery, although the previous antiplatelet agents were continued postoperatively. The patient's subcutaneous hematoma did not enlarge, and he was discharged in stable condition five days after the procedure. Three weeks after the procedure, the cervical hematoma had improved (Figure 5).

Discussion

Formation of cervical hematoma has been reported as a complication of carotid artery stenting¹. Reported causes of hematoma in-

clude arterial perforation by the guide wire and rupture of the carotid artery due to over-inflation of the PTA balloon^{2,3}. In all such reports, the cause has been arterial hemorrhage resulting in marked enlargement of the hematoma, compressing the trachea and requiring endotracheal intubation. Arterial hemorrhage in the cervical region is a life-threatening complication. Once the arterial perforation occurs and the extravasation of the contrast medium can be visualized, the patency of the airway must be immediately confirmed. Selective embolization of the ruptured artery is effective for hemostasis. A covered stent can be used for a laceration of the carotid artery. In patients who are given heparin, protamine sulfate can be administered to reverse heparin anticoagulation.

In the case we describe, the subcutaneous hematoma formed because of manual compression of the neck and cervical massage, a different mechanism of formation from those hitherto reported. Conceivable causes of the hemorrhage were that the tip of the aspiration catheter lacerated the carotid artery or that carotid massage to the arterial wall, damaged by a wire during the access to the lesion before stenting, induced the hemorrhage in the cervical region. Angiography was performed immediately after the appearance of the subcutaneous hematoma, but it showed no extravasation of contrast medium. The cause of the subcutaneous hematoma in this patient was therefore regarded as hemorrhage due to rupture of small subcutaneous vessels as a result of cervical massage. Hence, protamine sulfate was not used as a heparin antagonist, and the dual antiplatelet therapy was continued postoperatively so as not to increase the risk of in-stent thrombosis in the acute phase of stenting. The patient's postoperative course, with little enlargement of the hematoma and no compression or obstruction of the trachea, meaning that tracheal intubation was not required, supported the hypothesis of hematoma formation not related to arterial perforation or large artery laceration.

In the present case, manual compression of the neck was necessary because the aspiration catheter became caught on the stent strut. In cases such as this, appropriate use of an embolic protection device might prevent the occurrence of similar complications. Both proximal protection methods, involving obstruction of the common carotid and external carotid arteries using a balloon⁶, and distal protection

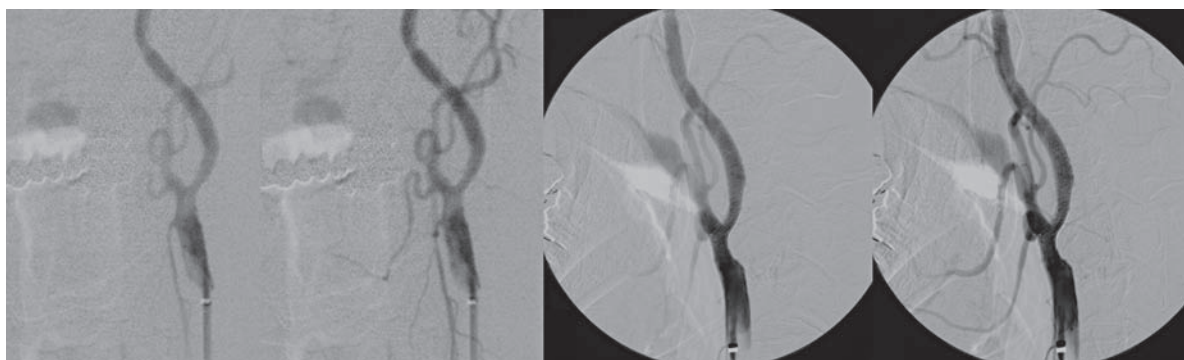


Figure 3 Left common carotid artery angiography. A) AP view, B) lateral view after stenting showing adequate dilatation of the stenotic lesion. No extravasation of the contrast medium is seen.

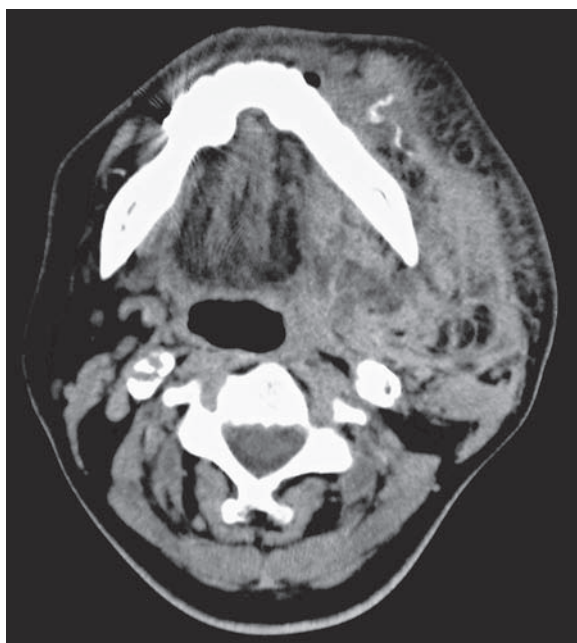


Figure 4 Non-contrast computed tomography, showing a large subcutaneous hematoma of the left cervical region and tracheal displacement to the right.

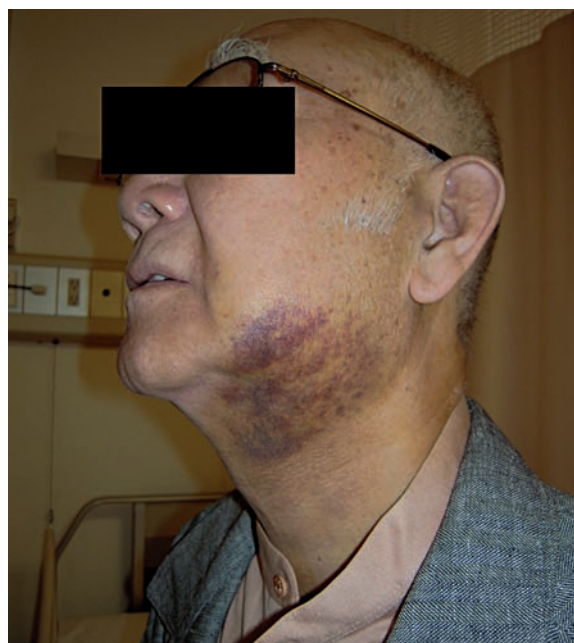

Figure 5 Left cervical region 3 weeks postoperatively. The cervical hematoma had improved.

methods using a filter protection device⁷ could be used. The proximal protection method has the disadvantage of requiring a 10-French sheath, making hemostasis difficult at the femoral artery, the sheath puncture site. If a filter protection device is used, this has the disadvantage that the capture catheter used to recover the filter often becomes caught on the stent strut. Whichever method is used, the use of plaque imaging to analyze plaque characteristics is important for the selection of a safe method of embolic protection⁸⁻¹¹.

Conclusion

We described a case of cervical subcutaneous hematoma formation occurring immediately after cervical massage during carotid artery stenting for cervical carotid artery stenosis. The cause of this subcutaneous hematoma was regarded as massage-induced rupture of small vessels. Cervical subcutaneous hematoma may occur as a result of cervical massage in patients undergoing adjuvant antiplatelet and anticoagulant therapy.

References

- 1 Bates ER, Babb JD, Casey DE Jr, et al. ACCF/SCAI/SVMB/SIR/ASITN 2007 clinical expert consensus document on carotid stenting: a report of the American College of Cardiology Foundation Task Force on Clinical Expert Consensus Documents (ACCF/SCAI/SVMB/SIR/ASITN Clinical Expert Consensus Document Committee on Carotid Stenting). *J Am Coll Cardiol.* 2007; 49: 126-170.
- 2 Ecker RD, Guidot CA, Hanel RA, et al. Perforation of external carotid artery branch arteries during endoluminal carotid revascularization procedures: consequences and management. *J Invasive Cardiol.* 2005; 17: 292-295.
- 3 Dieter RS, Ikram S, Satler LF, et al. Perforation complicating carotid artery stenting: the use of a covered stent. *Catheter Cardiovasc Interv.* 2006; 67: 972-975.
- 4 Yoshimura S, Enomoto Y, Kitajima H, et al. Carotid-compression technique for the insertion of guiding catheters. *Am J Neuroradiol.* 2006; 27: 1710-1711.
- 5 North American Symptomatic Carotid Endarterectomy Trial Collaborators. Beneficial effect of carotid endarterectomy in symptomatic patients with high-grade carotid stenosis. *N Engl J Med.* 1991; 325: 445-453.
- 6 Parodi JC, Ferreira LM, Sicard G, et al. Cerebral protection during carotid stenting using flow reversal. *J Vasc Surg.* 2005; 41: 416-422.
- 7 Yadav JS, Wholey MH, Kuntz RE, et al. Protected carotid-artery stenting versus endarterectomy in high-risk patients. *N Engl J Med.* 2004; 351: 1493-1501.
- 8 U-King Im JM, Young V, Gillard JH. Carotid-artery imaging in the diagnosis and management of patients at risk of stroke. *Lancet Neurol.* 2009; 8: 569-580.
- 9 Tsurumi A, Miyachi S, Hososhima O, et al. Can periprocedural hypotension in carotid artery stenting be predicted? A carotid morphologic autonomic pathologic scoring model using virtual histology to anticipate hypotension. *Interventional Neuroradiology.* 2009; 15: 17-28.
- 10 Biasi GM, Froio A, Diethrich EB, et al. Carotid plaque echolucency increases the risk of stroke in carotid stenting: the Imaging in Carotid Angioplasty and Risk of Stroke (ICAROS) study. *Circulation.* 2004; 110: 756-762.
- 11 Haraguchi K, Houkin K, Koyanagi I, et al. Evaluation of carotid plaque composition by computed tomography angiography and black blood magnetic resonance image. *Interventional Neuroradiology.* 2008; 14: 39-43.

Arihito Tsurumi, MD, PhD
Department of Neurosurgery,
National Hospital Organization Nagoya Medical Center
Tel.: +81-52-951-1111
Fax: +81-52-951-0664
E-mail: arihito@tsurumi.pro